

WORLD UNION
OF
WOUND HEALING SOCIETIES



WORLD UNION OF WOUND HEALING SOCIETIES
POSITION DOCUMENT

MANAGEMENT OF BIOFILM

The role of biofilm in delayed
wound healing

Biofilm management in practice

How is research advancing the
understanding of biofilm



PUBLISHER

Clare Bates

MANAGING DIRECTOR

Rob Yates



www.wuwhs.net

How to cite this document

World Union of Wound Healing Societies (WUWHS), Florence Congress, Position Document. *Management of Biofilm*. Wounds International 2016



Supported by an educational grant from B Braun

The views expressed in this publication are those of the authors and do not necessarily reflect those of B Braun

Produced by
Wounds International — a division of Omnia-Med Ltd
1.01 Cargo Works, 1-2 Hatfields, London, SE1 9PG

All rights reserved ©2016. No reproduction, copy or transmission of this publication may be made without written permission.

No paragraph of this publication may be reproduced, copied or transmitted save with written permission or in accordance with the provisions of the Copyright, Designs and Patents Act 1988 or under the terms of any licence permitting limited copying issued by the Copyright Licensing Agency, 90 Tottenham Court Road, London, W1P 0LP

Antimicrobial and multi-drug resistance loom large on the global healthcare landscape, in particular in the treatment of chronic, hard-to-heal wounds where current figures put the presence of biofilm in 60%-100% of non-healing wounds. While the role that biofilm play in the chronicity of wounds is still in infancy, it is becoming widely accepted that hard-to-heal wounds contain biofilm – and that somehow their presence delays or prevents healing.

Management of biofilm in chronic wounds is rapidly becoming a primary objective of wound care. However management of biofilm is an undeniably complex task. Beyond the basic steps of initial prevention (use of anti-biofilm agents), removal (debridement, desloughing) and prevention of reformation (use of antimicrobial agents), there are myriad patient, environmental and clinical parameters that must be considered when identifying a tailored solution.

Detection and localisation of biofilms in chronic wounds provide useful clinical information that helps assess and direct the effectiveness of debridement. Yet gaps in the knowledge base remain in detecting and localising biofilm. While existing guidelines (e.g. ESCMID 2015) do offer direction in diagnosis and treatment of biofilm infection, questions remain unanswered, including whether there are visual signs that might be useful in deciding whether or not to take a biopsy.

As the debate around whether or not biofilm can be seen with the naked eye gathers pace and new techniques (e.g. Nagakami and colleagues' 'biofilm wound map') come to light, there still remains a critical need for a 'point-of-care' biofilm detector that can detect the presence of biofilm in minutes, not hours or days.

While significant progress has been made in prevention, detection and management of biofilm, more research is needed to reduce the impact on patients and on healthcare systems alike.

In this Position Document, leading clinicians look at the role biofilm plays in delayed wound healing; the management of biofilm in practice, and how research – existing and yet to come – will further understanding of these bacterial communities.

Authors

Thomas Bjarnsholt, Costerton Biofilm Center, Department of Immunology & Microbiology, Faculty of Health and Medical Sciences, The University of Copenhagen, Denmark; Department of Clinical Microbiology, Rigshospitalet, Denmark

Rose Cooper, Cardiff School of Health Sciences, Cardiff Metropolitan University, Cardiff, UK

Jacqui Fletcher, Independent Consultant, UK

Isabelle Fromantin, Wounds and Healing Expert, Institut Curie, France

Klaus Kirketerp-Møller, Copenhagen Wound Healing Center, Bispebjerg University Hospital, Copenhagen, Denmark

Matthew Malone, Liverpool Hospital, South Western Sydney LHD, Australia; LIVE DIAB CRU, Ingham Institute of Applied Medical Research, Sydney, Australia

Greg Schultz, Institute for Wound Research, Department of Obstetrics & Gynecology, University of Florida, USA

Randy Wolcott, President, Professional Association and Research and Testing Lab of the South Plains, Texas, USA

The role of biofilms in delayed wound healing

Bacteria are often viewed as being single cells that multiply rapidly when in exponential growth, and are susceptible to antibiotics if not inherently resistant. Antimicrobial resistance and multi-drug resistance are an increasing problem across the globe, and are a current hot topic subject to much debate. Most clinicians involved in the treatment of wounds will utilise susceptibility patterns they receive from the clinical microbiology laboratory as a guide to determine which antibiotic(s) a patient requires. These decisions are often aided by international consensus guidelines, which are sufficient when managing acute infections^[1,2,3,4]. However, in cases of chronic infection, such as those seen for implantable medical devices, pulmonary infections of cystic fibrosis (CF) patients and chronic non-healing wounds, these guidelines may be inadequate. Why is this? How can we explain the quick resolution of infective symptoms using antimicrobial agents in patients with acute wounds, in comparison to the lethargic or non-response often noted in non-healing chronic wounds?

The answer is both complicated and also rather simple (Box 1, page 7). Bacteria can exist in at least two different phenotypic growth forms: the first being single, fast-growing cells i.e. the planktonic form; the second as aggregated communities of slow-growing cells in a biofilm form. All classic microbiology and development of antimicrobials have been based solely on planktonic paradigms, through methods developed in the early 1800s. It is considerably easier to grow bacteria using these methods, through shaken cultures or by spreading on an agar plate — and it is how bacteria presumably exist during acute infections. These methods are still widely accepted as ‘gold standard’ for depicting the pathogens of acute infections.

The picture for chronic infections is the complete opposite, however. In this case, a substantial amount of the bacteria reside in biofilms, where they are surrounded by a dense matrix of polysaccharides, free DNA (eDNA) of either bacterial or host origin, and proteins that attach tightly to the biofilm community and structures, protecting them from being engulfed and killed by neutrophils and macrophages. In addition, many of the bacteria are not dividing or metabolising rapidly, which causes them to become tolerant — almost all antibiotics kill only metabolically active bacteria by inhibiting critical bacterial enzymes. It is important to realise that most chronic infected wounds harbour several different bacterial species requiring different treatments, such as antibiotics^[5,6,7]. However, the different species are not necessarily within the same biofilm but rather scattered around in small, sovereign, single-species islands^[8,9,10].

In this review we will explore the implications of biofilms in human chronic, non-healing wounds, presenting evidence or hypothesis of how biofilms delay wound healing. We will also address the clinical conundrum of how to diagnose biofilm within wounds and the best methods in their treatment.

DEFINITION OF BIOFILM

Biofilms are frequently defined based on *in vitro* observations. Classic definitions often describe biofilms as bacteria attached to surfaces, encapsulated in a self-produced extracellular matrix and tolerant to antimicrobial agents (this includes antibiotics and antimicrobials). In addition, biofilm development is often described as a three-to-five-stage

Thomas Bjarnsholt, Costerton Biofilm Center, Department of Immunology & Microbiology, Faculty of Health and Medical Sciences, The University of Copenhagen and Department of Clinical Microbiology, Rigshospitalet, Denmark, **Greg Schultz**, Institute for Wound Research, Department of Obstetrics & Gynecology, University of Florida, **Klaus Kirketerp-Møller**, Copenhagen Wound Healing Center, Bispebjerg University Hospital, Copenhagen, Denmark, **Jacqui Fletcher**, Independent consultant and **Matthew Malone**, Liverpool Hospital, South Western Sydney LHD, Australia, LIVE DIAB CRU, Ingham Institute of Applied Medical Research, Sydney, Australia

“Antimicrobial resistance and multi-drug resistance are an increasing problem across the globe, and are a current hot topic subject to much debate”

scenario, beginning with single cells attaching to a surface, maturation of the biofilm and, lastly, dispersal of bacteria from the biofilm^[11,12,13]. *In vitro* observations, based on flow cell models utilising glass surfaces and fresh oxygenated culture media continuously flowing over the bacterium, differ greatly when compared to conditions within chronic wound infections^[14]. Here, the bacteria are not exposed to a continuous flow of fresh media and are not attached to a glass surface (or indeed any surface)^[6,10]. *In vivo* chronic wound biofilm are often encapsulated in a matrix, which includes host material, making dispersal problematic.

Therefore, using *in vitro* observations to define, diagnose and treat biofilms in chronic infections may provide a misguided impression^[15]. There are, however, commonalities between *in vitro* and *in vivo* evidence that can help in providing a definition of a biofilm. These include:

- Aggregation of bacteria
- Some sort of matrix that is not restricted to self-produce as it can also be of host origin
- Extreme tolerance and protection against most antimicrobial agents and the host defence.

We suggest following this simplified definition in order to define biofilms in chronic infections: *an aggregate of bacteria tolerant to treatment and the host defence.*

HOW DO BIOFILM COMMUNITIES DIFFER FROM PLANKTONIC BACTERIA?

All planktonic bacteria are single cells that are usually fast growing and are rarely observed directly in infections, except during severe conditions such as sepsis^[14]. However, we assume that during acute infections bacteria are of the planktonic phenotype, since they are susceptible to antimicrobial agents with targeted treatments causing an abrupt resolution of symptoms.

In vivo evidence has suggested biofilm phenotypes differ markedly in both their physiology and activity when compared with planktonic cells. The bacteria are aggregated and difficult to treat, if not impossible, somehow evading host defences^[3,14]. Often the bacteria are embedded in a matrix which can be produced by the bacteria or is of host origin. The exact composition of extracellular polymeric substance (EPS) varies according to the microorganisms present, but generally comprise polysaccharides, proteins, glycolipids and extracellular DNA (eDNA)^[16, 17, 18].

Microelectrode studies have further identified anoxic regions within a biofilm, resulting in lower bacterial cell metabolic activity^[19,20,21]. This contributes in part to the inherent resilience of biofilms to antimicrobial treatments.

PREVALENCE OF BIOFILMS IN CHRONIC WOUNDS

Less than 10 studies have visualised biofilms in non-healing chronic wounds using the accepted approaches of microscopy with or without molecular analysis^[6, 9,10,21-24]. These studies identified the presence of biofilms in 60% to 100% of samples. In light of the heterogeneity and spatial distribution of biofilms within chronic wounds, the failure of sampling techniques to capture tissue ‘housing’ biofilm could potentially see the ‘true’ prevalence being closer to 100%^[7,10].

DETECTING BIOFILMS IN CHRONIC WOUNDS

We have addressed these issues in reverse, for which our rationale will become apparent. Current accepted methods to visualise biofilm from tissue samples have been confined primarily to the use, by researchers, of high-powered microscopes (scanning electron microscopy — SEM; confocal laser scanning microscopy — CLSM) alone or in combination with molecular DNA sequencing techniques that use fluorescent probes to determine the presence or absence and location of bacteria. Even these approaches have limitations, in particular the heterogeneous distribution of bacteria within a wound.

This makes the choice of wound sampling challenging; a tissue biopsy is ‘gold standard’ but will only collect bacteria from a small area, significantly increasing the chances that some relevant bacteria will be missed completely^[7]. In comparison, the use of superficial swabs using the Levine technique can sample a broad area but will only collect the bacteria on the wound surface, and this may not necessarily reflect the microbiota^[25,26].

There has been much debate over whether biofilms, which are microscopic in nature, can be seen with the naked eye. In differing human health and disease conditions biofilms, when left to thrive, may show evidence at a macroscopic level, one example being oral plaque^[27]. However, the picture is less clear for chronic wounds. Some clinicians have used rhetoric to promote what they believe are ‘clinical cues’ of biofilm presence through naked-eye observations that are not based on scientific rigour^[2,28,29]. Such signs have included; a shiny, translucent, slimy layer on the non-healing wound surface^[28,29]; the presence of slough or fibrin and gelatinous material reforming quickly following removal, in contrast to slough and other devitalised tissue or fibrin that often takes longer to reform^[29,30,31].

Currently, there is no ‘gold standard’ diagnostic test to define the presence of wound biofilm and no quantifiable biomarkers. This may pose a significant clinical challenge given that distinguishing between planktonic or biofilm phenotype pathogenicity in chronic wound infection is a major barrier to effective treatment.

Based on our previous statement that ‘all non-healing chronic wounds potentially harbour biofilms’, relying on anecdotal visual cues is unnecessary. We propose that clinicians should ‘assume all non-healing, chronic wounds that have failed to respond to standard care have biofilm’ and, therefore, treatments should be targeted towards this. We suggest that clinical suspicion of the presence of biofilm be raised in those patients where chronic wound infections have failed to respond adequately to antimicrobial agents and standard wound care treatment, or where chronic wound infections experience periods of quiescence that alternate with acute episodes^[32]. These signs and symptoms are based on current evidence identifying that biofilms cannot be eradicated by antimicrobial agents, so it is fair to assume that a non-healing, chronic wound contains bacteria in the biofilm phenotype.

HOW DO BIOFILMS INHIBIT WOUND HEALING?

The exact mechanisms by which biofilm impairs the healing processes of wounds remain ambiguous. Current data suggest the wound is kept in a vicious inflammatory state preventing normal wound healing cycles from occurring. The pathways behind this are not clear, but several systemic and local factors contribute to the occurrence and maintenance of a chronic wound. At the systemic level, physiological factors include diabetes mellitus, venous insufficiency, malnutrition, malignancy, oedema, repetitive trauma to the tissue and impaired host response. The majority of chronic wounds will heal if the predisposing factors are treated properly; for example, oedema reduction in venous leg ulcers, off-loading in diabetic foot ulcers and pressure ulcers, along with moist wound healing principles.

At local level bacteria colonise all chronic wounds; the most commonly reported are *Staphylococcus aureus* and *Pseudomonas aeruginosa* — two renowned biofilm formers. In a paper by Gjødsbøl et al^[33], 93.5% of chronic leg ulcers contained *S. aureus* and 52.2% harboured *P. aeruginosa*, but only the ulcers with *P. aeruginosa* were characterised by larger wound sizes and slower healing rates. This could be explained by the ability of *P. aeruginosa* to eliminate polymorphonuclear leucocytes (PMN) by secreting rhamnolipid^[34]. This glycolipid is controlled through the quorum sensing system and is probably one of the main mechanisms behind the lack of eradication of *P. aeruginosa* in chronic wounds.

In expanding further on the role of PMN, Ennis et al (2000)^[26] stated that chronic wounds were ‘stunned in the inflammatory phase of healing’. In normal wound healing trajectories this phase would be preceded by a proliferative phase, where the function of PMN are gradually overtaken by macrophages, and fibroblasts begin to rebuild the tissue^[26].

“We propose that clinicians should ‘assume all non-healing, chronic wounds that have failed to respond to standard care have biofilm’ and, therefore, treatments should be targeted towards this”

Box 1: Biofilms: challenging current wound management practices

Biofilms present several challenges for traditional wound management and wound healing. Firstly, locating biofilms in wound beds can be difficult, and clinicians are usually limited to debriding areas that have secondary signs of biofilms — ‘wound slough’ and other surface signs of local inflammation.

Secondly, optimal sampling of both the surface and subsurface regions of wound beds is difficult and the bacteria are very heterogeneously distributed. Subsequent identification of biofilm bacteria is therefore a challenge because a standard clinical microbiology lab is not aware of the more complicated nature of biofilms and does not process wound samples to disperse biofilms adequately in order that bacteria can be cultured by standard plate growth assays.

The biofilms interfere with normal wound healing, apparently by ‘locking’ the wound bed into a chronic inflammatory state that leads to elevated levels of proteases (matrix metalloprotease and neutrophil elastase) and reactive oxygen (ROS) that damage proteins and molecules that are essential for healing. A large percentage of bacteria in biofilm communities are metabolically dormant, which generates tolerance to antibiotics. Highly chemically reactive disinfectant molecules frequently react with the components of the biofilm exopolymeric matrix, depleting their concentration and impeding their penetration deep into the biofilm matrix.

The consequences, therefore, of sustained, *in situ* necrosis by bacterial cells could explain both the constant influx of PMN into chronic wounds containing *P. aeruginosa* and the resulting localised release of proteolytic enzymes that are pro-inflammatory^[35]. Unfortunately, we cannot postulate the mechanism responsible for this phenomenon in non-*Pseudomonas* infested wounds^[36].

In 2015, Marano et al^[37] identified that migration and proliferation of human epidermal keratinocytes were decreased by derivatives from biofilms of *P. aeruginosa* and *S. aureus*. Employing proteomic analysis allowed Marano et al to map *S. aureus* activity to a protein, while *P. aeruginosa* activity was more likely due to a small molecule^[37]. The several proteins revealed through proteomic analysis had putative links to delayed wound healing. These included α -haemolysin, alcohol dehydrogenase, fructose-bisphosphate aldolase, lactate dehydrogenase and epidermal cell differentiation inhibitor.

A second research area of interest has suggested that infecting bacterial biofilms contribute to a localised low oxygen tension within the wound. Early *in vitro* studies using microelectrodes identified discrete areas of significant oxygen depletion within biofilms^[38]. Further studies employing microelectrodes with CLSM, identified micro-domains with different areas of the biofilm harbouring alternate biochemical environments, including alterations in pH and oxygen^[39]. The creation of anoxic areas within biofilm may explain the presence of anaerobes in mixed-species biofilms. The anoxic conditions have also been seen in chronic pulmonary infections in patients with CF^[40]. Within a chronically infected CF lung, PMN have been shown primarily to consume oxygen resulting in oxygen depletion that suffocates the bacteria causing lower metabolic activity^[19,20].

In 2016 data by James and colleagues provided further evidence to support a concept of localised low oxygen tensions contributing to wound chronicity^[21]. Using oxygen microsensors and transcriptomics (examining microbial metabolic activities) to study *in situ* biofilms, James and colleagues identified steep oxygen gradients and induced oxygen-limitation stress responses from bacteria. Taken collectively, these data support the concept that biofilm helps to maintain localised low oxygen tensions in the wound, thus contributing to chronicity^[21].

The presence of the highly persistent biofilms results in a chronic inflammatory state within the wound bed that leads to elevated levels of proteases (matrix metalloprotease and neutrophil elastase) and reactive oxygen species (ROS) that damage the proteins and molecules that are vital for healing^[41]. By ‘locking’ the wound bed into a chronic inflammatory state, biofilms disrupt normal wound healing.

Our current understanding of how biofilms inhibit wound healing remains scarce, but the two examples above postulate how wound healing can be delayed. It is also apparent that systemic factors contribute to a paradoxical state of play. It is possible that in some cases the bacterial biofilm is the primary inhibitor of wound healing. Yet in other circumstances some of these wounds will heal if the original cause of the wound is addressed (e.g. compression therapy for a venous leg ulcer or off-loading a diabetic foot ulcer). Certainly some chronic wounds will not heal, despite proper treatment of local impairment. These wounds may prove to have especially virulent bacterial content.

The wound treadmill (Figure 1) illustrates this paradox. The force driving clockwise momentum is the sum of the virulence of the bacteria while the figure in the centre that is driving counterclockwise movement represents the sum of the healing capacity of the patient. The healthier the patient (local and systemically), the more virulent the bacteria need to be to prevent or halt healing. This implies that ‘weak’ patients will suffer from even the most opportunistic infections. The current treatment of chronic wounds aims at reducing local impairment by modalities such as compression, off-loading and moist wound dressings. In addition, the systemic impairments are managed by correcting the malnourished patient or by adjusting glycosylated haemoglobin (HbA1c) levels.

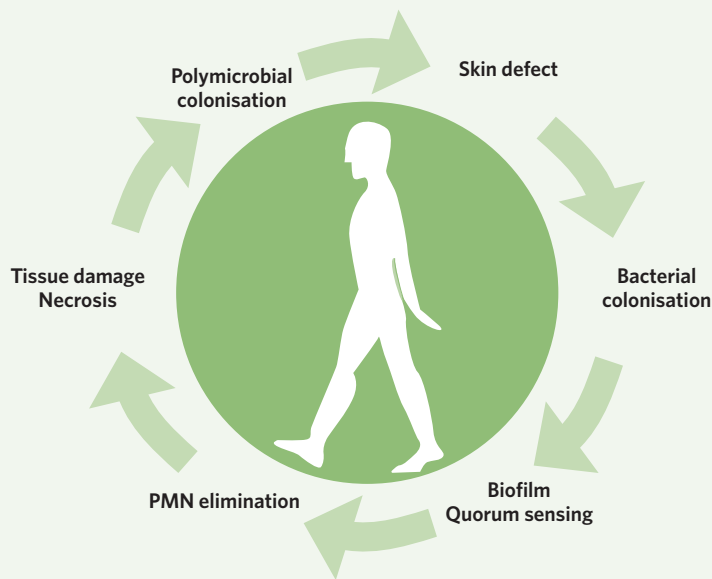
CONCLUSION

It is apparent from this review that diagnosing, treating and understanding the role biofilms play in the chronicity of wounds is still in its infancy. Scientific endeavour into this niche area is gathering pace with mounting evidence suggesting we are on the right track. It is becoming widely accepted that non-healing, chronic wounds contain biofilms, and that these somehow delay or prevent wound healing. More focused research ensuring standardisation between study methodologies, such as optimal sampling techniques, will ensure comparability between studies. New treatment paradigms are required, but in order to achieve this the development of *in vitro* models that mimic the actual wound environment are required.

Lastly, more interdisciplinary collaborations between front-line clinicians and basic scientists are needed to bridge the gap between what is clinically relevant to patients suffering with biofilm-related complications.

Figure 1 | Wound Treadmill

The Wound Treadmill (Figure 1) illustrates the paradox in chronic wounds: why do some patients develop chronic wounds while others do not? The person in the centre is forcing the wheel to turn counterclockwise and the driving force on the outer rim is the combined virulence of the bacteria. Hence the ‘stronger’ the person the more virulence is required from the bacteria to prevent healing. See text for further explanation.



REFERENCES

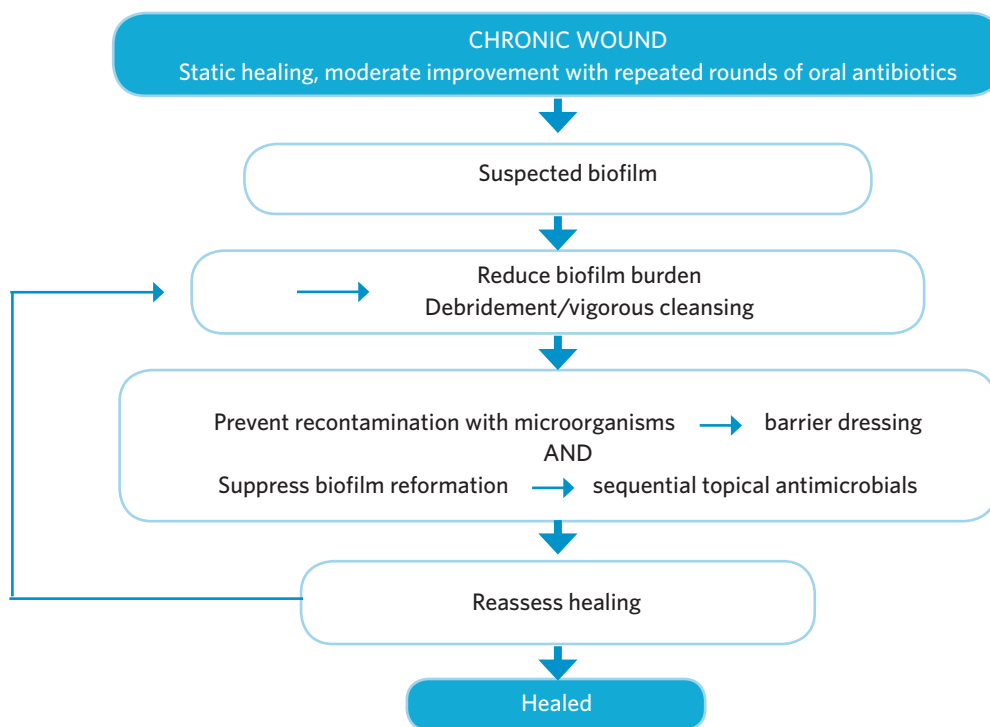
1. Gottrup F, Apelqvist J, Bjarnsholt T et al (2013). EWMA document: Antimicrobials and non-healing wounds. Evidence, controversies and suggestions. *J Wound Care* 2012; 22(5 Suppl): S1-89.
2. Metcalf DG, Bowler PG, Hurlow J. A clinical algorithm for wound biofilm identification. *J Wound Care* 2014; 23(3): 137-2.
3. Høiby N, Bjarnsholt T, Moser C et al. ESCMID guideline for the diagnosis and treatment of biofilm infections 2014. *Clin Microbiol Infect* 2015; 21 Suppl 1: S1-25.
4. Lipsky BA, Aragon-Sanchez J, Diggle M et al. IWGDF guidance on the diagnosis and management of foot infections in persons with diabetes. *Diabetes Metab Res Rev* 2015; 32(Suppl 1): 45-74.
5. Dowd SE, Sun Y, Secor PR et al. Survey of bacterial diversity in chronic wounds using pyrosequencing, DGGE, and full ribosome shotgun sequencing. *BMC Microbiol* 2008; 8(1):1.
6. James GA, Swogger E, Wolcott R et al. Biofilms in chronic wounds. *Wound Repair Regen* 2008; 16(1): 37-44.
7. Thomsen TR, Aasholm MS, Rudkjøbing VB et al. The bacteriology of chronic venous leg ulcer examined by culture-independent molecular methods. *Wound Repair Regen* 2010; 18(1): 38-49.
8. Burmølle M, Thomsen TR, Fazli et al. Biofilms in chronic infections — a matter of opportunity — monospecies biofilms in multispecies infections. *FEMS Immunol Med Microbiol* 2010; 59(3): 324-36.
9. Fazli M, Bjarnsholt T, Kirketerp-Møller K et al. Non-Random Distribution of *Pseudomonas aeruginosa* and *Staphylococcus aureus* in Chronic Wounds. *J Clin Microbiol* 2009; 47(12): 4084-9.
10. Kirketerp-Møller K, Jensen PØ, Fazli M et al. Distribution, organization, and ecology of bacteria in chronic wounds. *J Clin Microbiol* 2008; 46(8): 2717-22.
11. Costerton JW, Stewart PS and Greenberg EP. Bacterial biofilms: a common cause of persistent infections. *Science* 1999; 284(5418): 1318-22.
12. Sauer K, Camper AK, Ehrlich GD et al. *Pseudomonas aeruginosa* displays multiple phenotypes during development as a biofilm. *J Bacteriol* 2002; 184(4): 1140-54.
13. Klausen M, aes-Jørgensen A, Molin S, Tolker-Nielsen T. Involvement of bacterial migration in the development of complex multicellular structures in *Pseudomonas aeruginosa* biofilms. *Mol Microbiol* 2003; 50(1): 61-8.
14. Bjarnsholt T, Alhede, M, Eckhardt-Sorensen SR et al. The in vivo biofilm. *Trends Microbiol* 2013; 21(9): 466-74.
15. Roberts AE, Kragh KN, Bjarnsholt T, Diggle SP. The Limitations of in vitro experimentation in understanding biofilms and chronic infection. *J Mol Biol* 2015; 427(23): 3646-61.
16. Sutherland I. Biofilm exopolysaccharides: a strong and sticky framework. *Microbiology* 2001; 147(Pt 1): 3-9
17. Hall-Stoodley L, Stoodley P. Evolving concepts in biofilm infections. *Cell Microbiol* 2009; 11(7): 1034-43
18. Flemming HC, Neu TR, Wozniak DJ. The EPS matrix: the "house of biofilm cells". *J Bacteriol* 2007; 189(22): 7945-47
19. Kolpen M, Hansen CR, Bjarnsholt T. Polymorphonuclear leucocytes consume oxygen in sputum from chronic *Pseudomonas aeruginosa* pneumonia in cystic fibrosis. *Thorax* 2010; 65(1): 57-62.
20. Kragh KN, Alhede M, Jensen PØ et al. Polymorphonuclear leukocytes restrict growth of *Pseudomonas aeruginosa* in the lungs of cystic fibrosis patients. *Infect Immun* 2014; 82(11): 4477-86.
21. James GA, Zhao AG, Usui M et al (2016). Microsensor and transcriptomic signatures of oxygen depletion in biofilms associated with chronic wounds. *Wound Repair Regen* 2016; doi: 10.1111/wrr.12401.
22. Han A, Zenilman JM, Melendez JH et al. The importance of a multifaceted approach to characterizing the microbial flora of chronic wounds. *Wound Repair Regen* 2011; 19(5): 532-41.
23. Neut D, Tijdens-Creusen EJ, Bulstra SK et al. Biofilms in chronic diabetic foot ulcers — a study of 2 cases. *Acta Orthop* 2011; 82(3): 383-385.
24. Oates A, Bowling FL, Boulton AJ, et al (2014). The visualization of biofilms in chronic diabetic foot wounds using routine diagnostic microscopy methods. *J Diabetes Res* 2014, 153586.
25. Levine NS, Lindberg RB, Mason Jr AD, Pruitt Jr BA. The quantitative swab culture and smear: A quick, simple method for determining the number of viable aerobic bacteria on open wounds. *J Trauma* 1976; 16(2): 89-94.
26. Ennis WJ, Meneses P. Wound healing at the local level: the stunned wound. *Ostomy Wound Manage* 2000; 46(1A Suppl): 395-485.
27. Marsh PD, Bradshaw DJ. Dental plaque as a biofilm. *J Ind Microbiol* 1995; 15(3): 169-75.
28. Lenselink E, Andriessen A. A cohort study on the efficacy of a polyhexanide-containing biocellulose dressing in the treatment of biofilms in wounds. *J Wound Care* 2011; 20(11): 534, 536-34, 539.
29. Hurlow J, Bowler PG. Potential implications of biofilm in chronic wounds: a case series. *J Wound Care* 2012; 21(3): 109-10, 112, 114.
30. Phillips P L, Fletcher J, Shultz G S. *Biofilms Made Easy*. Wounds International 2010; 1(3): 1-6.
31. Hurlow J, Bowler PG. Clinical experience with wound biofilm and management: a case series. *Ostomy Wound Manage* 2009; 55(4): 38-49.
32. Costerton W, Veeh R, Shirliff M et al. The application of biofilm science to the study and control of chronic bacterial infections. *J Clin Invest* 2003; 112(10): 1466-77.
33. Gjødsbøl K, Christensen JJ, Karlsmark T et al. Multiple bacterial species reside in chronic wounds: a longitudinal study. *Int Wound J* 2006; 3(3):225-31.
34. Jensen PØ, Bjarnsholt T, Phipps R et al. Rapid necrotic killing of polymorphonuclear leukocytes is caused by quorum-sensing-controlled production of rhamnolipid by *Pseudomonas aeruginosa*. *Microbiology* 2007; 153(Pt 5): 1329-38.
35. Wolcott RD, Rhoads DD, Dowd S E. Biofilms and chronic wound inflammation. *J Wound Care* 2008; 17(8): 333-41.
36. Bjarnsholt T, Kirketerp-Møller K, Jensen PØ et al. Why chronic wounds will not heal: a novel hypothesis. *Wound Repair Regen* 2008; 16(1): 2-10.
37. Marano RJ, Wallace HJ, Wijeratne D et al. Secreted biofilm factors adversely affect cellular wound healing responses in vitro. *Scientific Rep* 2015; 17(5): 13296.
38. de Beer D, Stoodley P, Roe F, Lewandowski Z. Effects of biofilm structures on oxygen distribution and mass transport. *Biotechnol Bioeng* 1994; 43(11): 1131-8.
39. Lawrence JR, Swerhone GD, Kuhlicke U, Neu TR. In situ evidence for microdomains in the polymer matrix of bacterial microcolonies. *Can J Microbiol* 2007; 53(3): 450-8.
40. Worlitzsch D, Tarran R, Ulrich M et al. Effects of reduced mucus oxygen concentration in airway *Pseudomonas* infections of cystic fibrosis patients. *J Clin Invest* 2002; 109(3): 317-325.
41. Mast BA, Schultz GS. Interactions of cytokines, growth factors, and proteases in acute and chronic wounds. *Wound Repair Regen* 1996; 4(4):411-20.

Biofilm management in practice

The prevention and management of biofilm in chronic wounds is rapidly becoming a primary objective of wound care, with the presence of biofilm acknowledged as a leading cause of delayed wound healing^[1-4].

Figure 1 depicts the basic principles of wound management for cases where wounds have stalled during healing in spite of repeated antibiotic treatment, and so presence of biofilm may be suspected. This article looks at when to treat a suspected biofilm, various strategies for its prevention and treatment, how these strategies may be combined for optimum success, and principles for monitoring this success.

Figure 1 | Principles of wound biofilm management^[5]



Jacqui Fletcher, Independent Nurse Consultant, UK and

Randall D Wolcott, President, Professional Association and Research and Testing Lab of the South Plains, Texas, USA, **Isabelle Fromantin**, Wounds and Healing Expert, Institut Curie, France

While acute infections tend to produce the classic signs and symptoms of wound infection, such as inflammation, pain, heat, redness and swelling^[6], microbes growing as biofilm produce a distinctly different pattern, often recognised as chronic infection^[7].

Systemic treatment strategies are required for infected chronic wounds, whereas in non-infected wounds where the presence of biofilm is impeding healing, strategies can be adopted to break up the biofilm. Alternately, attempts can be made to prevent initial biofilm formation in patients or wounds judged to be at high risk^[8].

Targeted therapies could be used to improve healing in cases where microbial biofilm is a causal component of chronic wounds as opposed to non-pathogenic colonisation; for example:

- Early use of systemic antibiotics directed at planktonic bacteria
- Unique strategies to make microbes more susceptible to antimicrobials for clearance by the host immune system
- Therapies directed at preventing a prolonged inflammatory component of wound healing^[9].

With this in mind, it is important that novel strategies to prevent and treat biofilm are developed^[3], which confer:

- Preventative action, interfering with either microbial attachment or processes involved in biofilm maturation or removal, and/or disruption of mature biofilm
- Action against existing biofilm, removing or disruption of the biofilm and prevention of reformation.

WHEN TO TREAT A BIOFILM

Expertise in chronic wound treatment, particularly strategies for treating infected wounds and recognition of biofilm, is vital in order to ensure patients receive optimum treatment. The Wounds at Risk (WAR) score was devised to aid decision-making in antimicrobial use (specifically polyhexanide) where there was previously no method to accurately predict infection risk in chronic wounds. The scoring system considers the quantity and virulence of a wound's pathogenic bioburden and the patient's immune competence, but provides no support for recognition of biofilm or suggestions for debridement. The existence of diagnostics to support detection of biofilm may render the WAR score more helpful^[10].

The actual identification of biofilm requires sophisticated laboratory techniques such as confocal laser scanning microscopy (CLSM), scanning electron microscopy (SEM) or molecular techniques for definition^[11]. Standard culture microbiology procedures only detect planktonic bacteria, so a different process must be used to detect bacteria in biofilms; typically, samples are treated initially to kill all planktonic bacteria, then the biofilm is physically dispersed with ultrasonic energy and cultured on nutrient agar plates to determine the extent of biofilm presence^[5].

Identification of biofilm in clinical practice is also difficult, with few guidelines available to facilitate its recognition. Keast et al (2014)^[5] propose four main features that may increase suspicion of the biofilm presence, as follows:

1. Antibiotic failure
2. Infection of >30 days' duration
3. Friable granulation tissue
4. A gelatinous material easily removed from wound surface that quickly rebuilds.

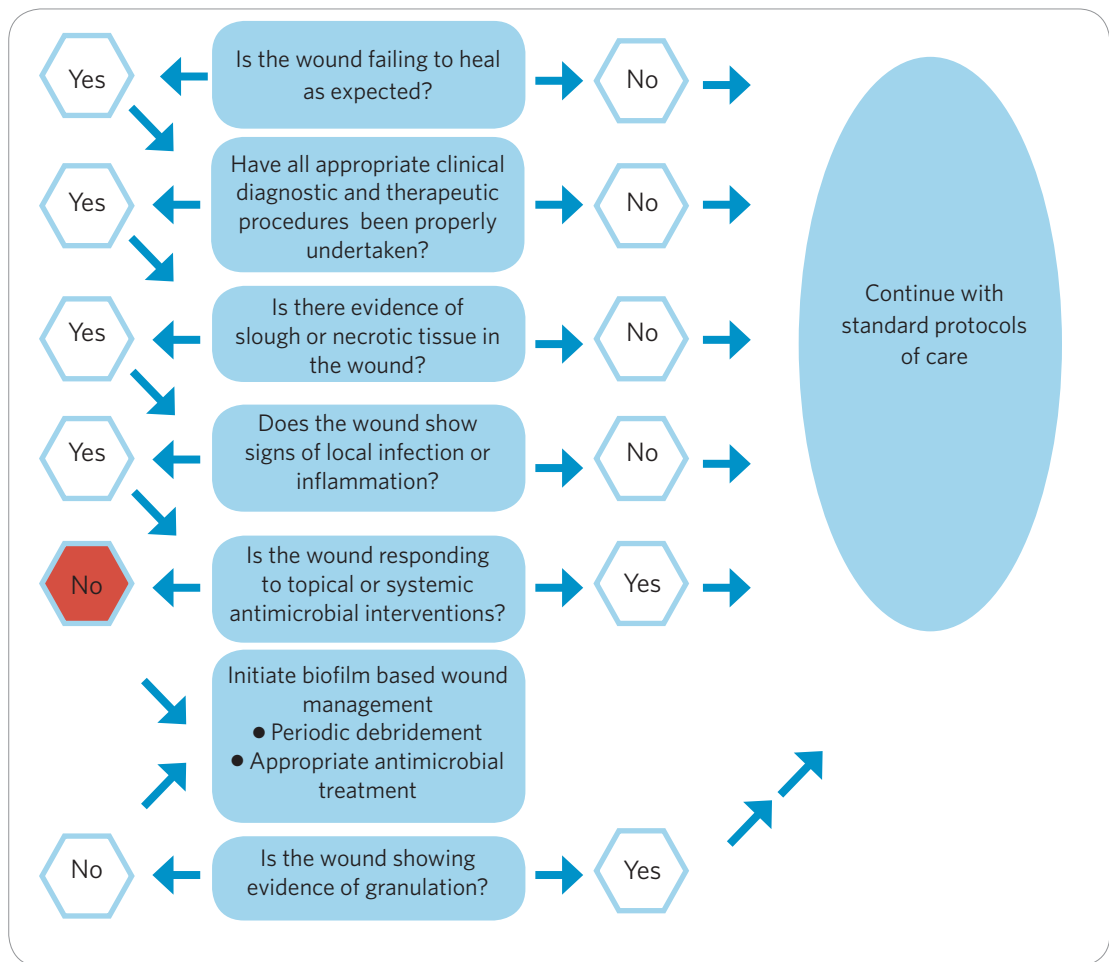
A recent study that collated current data regarding appearance, behaviour and clinical indicators associated with biofilm suggested that, on occasion, there may be visual cues suggestive of the presence of biofilm in the wound bed. A number of 'non-visual' clinical cues were also identified: signs of local infection, failure of antimicrobials, culture-negative swabs or recalcitrance of the wound despite all other factors being addressed. The authors suggested an algorithm incorporating both visual and non-visual cues could facilitate more effective biofilm-based wound management^[12].

However, there is no evidence to date that biofilm appears as a 'layer of slime' on the wound surface, so Percival et al (2015)^[13] argue that in the absence of any such scientific

evidence, manifestation of a slimy, translucent layer can be a crude and often misleading visual marker. They propose an approach to biofilm identification similar to Keast et al^[5], based on the hierarchical questions below. Where the answer is ‘no’, standard care should be continued; where the answer is ‘yes’, there is progression to the next question. If the answer to 5 is ‘no’, then biofilm-based wound management should be initiated (Figure 2)^[13].

1. Is the wound failing to heal as expected?
2. Have all appropriate clinical diagnostic and therapeutic procedures been properly undertaken?
3. Is there evidence of slough or necrotic tissue in the wound?
4. Does the wound show signs of a local infection or inflammation?
5. Is the wound responding to topical or systemic antimicrobial interventions?

Figure 2 |
Algorithm to detect suspected biofilm^[13]



HOW TO TREAT A BIOFILM

Strategies for prevention and treatment of biofilm

Once the likelihood of biofilm presence is established, an appropriate treatment strategy should be determined, taking into account that there are several stages of biofilm formation. A proactive approach to treatment recognises that there is no one-step solution for treatment of biofilm, but aims to reduce burden and prevent its reconstitution^[14].

Wolcott (2015)^[15] states that: ‘Biofilm-based wound care is predicated on using multiple different treatment strategies simultaneously including antibiotics, anti-biofilm agents,

Table 1: Potential anti-biofilm agents		
Mode of action	Examples	Further details
Interference with biofilm surface attachment	Lactoferrin Ethylenediamine-tetraacetic acid (EDTA) Xylitol Honey	As part of the innate human response mechanism, lactoferrin binds to cell walls causing destabilisation, leakiness and, ultimately, cell death ^[17] . EDTA has been used as a permeating and sensitising agent for biofilm conditions in dentistry and other fields ^[18] . Xylitol (an artificial sweetener) and honey have also been shown to block attachment ^[17]
Interference with quorum sensing, a mechanism of chemical signalling or communication between the cells within the biofilm	Farnesol Iberin Ajoene Manuka honey	Several agents block or interfere with quorum sensing, including: <ul style="list-style-type: none"> • Farnesol • Iberin (from horseradish) • Ajoene (from garlic) Manuka honey has also been shown to down-regulate 3 of the 4 genes responsible for the quorum sensing process ^[17]
Disruption of the extracellular polymeric substance (EPS), a protective matrix secreted by and surrounding the biofilm	EDTA	EDTA supports and enhances topical antimicrobials by disrupting the EPS in which microorganisms are encased ^[18] . Proprietary products also exist that claim, among their actions, to disrupt the EPS ^[19]
False metabolites	Gallium, Xylitol	Low doses of Gallium and Xylitol have been shown to interfere with biofilm formation ^[20]
Disruption of existing biofilm	Betaine (combination of PHMB and betaine)	Current solutions favoured in the disruption of biofilm contain surfactants, such as betaine, which lower the surface tension of the medium in which they are dissolved, allowing dirt and debris to be lifted and suspended in the solution ^[21,22]

selective antimicrobials and frequent debridement.' Moreover, Hurlow et al (2015)^[16] caution that while focused activity against the biofilm is paramount, maximising the host response must also be addressed with attention paid to all local and underlying causes of delayed wound healing.

Potential anti-biofilm agents

In practice, physical biofilm disruption in the form of debridement and/or cleansing, followed by use of antimicrobial agents (such as PHMB or silver) to prevent its reformation, is the primary anti-biofilm option available to clinicians at present; this is discussed in more detail below^[4]. However, various potential anti-biofilm agents that interfere with elements of their formation or support and enhance the effect of antimicrobials have been investigated; these are summarised in Table 1, categorised by their modes of action. Where such an agent is chosen, this choice should be based on factors including the biocidal capability and length of activity of the active agent, and the capability of the carrier dressing to manage presenting symptoms, such as increased levels of exudate.

The importance of wound bed preparation

Preparation of the wound bed, including cleansing and debridement, are important principles of wound management, since wounds must be clean to heal^[23]. The concept of TIME (Tissue, Infection/Inflammation, Moisture, Edge of wound) is a widely accepted standard of wound management. In the intervening 10 years there have been important developments including, understanding of biofilm presence (and the need for a simple diagnostic), the importance of clinical recognition of infection, and the value in repetitive and maintenance debridement and cleansing of wounds, which is paramount^[11].

Where either slough or necrosis is present in a wound, this non-viable tissue should be removed as it may support the attachment and development of biofilm^[24]. The speed of tissue removal should be conducted according to the patient’s ability to undergo the procedure, the skill and competence of the practitioner, and the safety of the environment

in which the technique is to be performed^[25]. A distinction has recently been drawn between removal of slough ('desloughing')^[24] and that of necrotic tissue (debridement). In order to ensure effectiveness, it is proposed that neither therapy be conducted as a one-off, with both maintenance debridement and desloughing recommended.

Various debridement techniques are available, from surgical (performed in theatre, back to healthy bleeding tissue), and autolytic (use of dressings to facilitate removal of necrotic tissue^[23-24]) through to debridement pads and cloths^[26,27]. The current cleansing solutions favoured to assist in the disruption of biofilm contain surfactants, which lower the surface tension of the medium in which they are dissolved, making it easier to lift off dirt/debris and suspend this in solution, to avoid re-contamination of the wound^[21,22]. Solutions may be added directly to the wound, used as soaks on gauze or used as part of an instillation alongside negative pressure wound therapy^[28].

Based on current literature, the combination of polyhexanide and betaine, a surfactant, has been identified as effective for autolytic wound debridement. In a randomised controlled trial conducted across six Italian centres (June 2010 — December 2013), the solution was found to promote wound bed preparation, reduce inflammatory signs, and accelerate healing of vascular leg ulcers, as well as having a lasting barrier effect. Indeed, compared with normal saline, the solution was statistically significantly superior ($p < 0.001$) in terms of both wound improvement and reduction in inflammatory signs^[23].

Using antimicrobials following debridement to prevent reformation

Once the wound has been appropriately cleansed and as much non-viable tissue removed as is comfortable for the patient, it is suggested that an antimicrobial product be used to prevent reformation of the biofilm (Figure 1)^[5]; for example, anti-biofilm dressings containing antimicrobials agents like PHMB, silver and a surfactant^[29]. A number of active antimicrobial agents have been linked to biofilm treatment:

- Acetic acid^[30]
- Honey^[3,31]
- Iodine^[18,32-34]
- PHMB^[18,35]
- Silver^[18,33-36].

Importantly, these must be used following physical disruption of the biofilm by cleansing (i.e. with a solution containing a surfactant combined with an antimicrobial, such as PHMB with betaine) and debridement, in order to ensure antimicrobial efficacy (Figure 1). In addition, other products without an active antimicrobial agent have demonstrated anti-biofilm activity, such as products that work by irreversibly binding the bacteria to dialkyl carbamoyl chloride (DACC)-coated dressings^[37]; the microorganisms are removed along with the dressing and there is no cell debris remaining in the wound^[38].

HOW TO MONITOR SUCCESS

It is not possible to say definitely when a biofilm has been removed, since there is a lack of categorical signs and tests for its identification. As such, clinicians must use healing progression as a marker for success, also taking into account reduction in other parameters such as levels of slough and production of exudate^[14]. Indeed, when measuring the outcome of biofilm-based wound management, the primary factors that led to initial suspicion of biofilm should be reviewed:

- Is the wound failing to heal despite appropriate treatment?
- Is the wound demonstrating signs and symptoms of infection, which do not resolve with appropriate antimicrobial agents?

- Is there a gelatinous material on the wound surface, which does not resolve?

If these have been resolved then it may be assumed that the treatment plan has been successful.

Any product selected should be used for an appropriate length of time and continued for a minimum of 7-10 days before a decision is made to continue or discontinue use. A recent consensus recommended utilising a '2-week challenge' to determine the efficacy of an antimicrobial (specifically silver dressings). After 2 weeks it should be determined whether the wound has improved and whether there are any continuing signs of infection^[5].

It is suggested that a wound with suspected biofilm should be debrided and cleansed regularly, since it is difficult to remove all of the biofilm, which has the potential to regrow and form mature biofilm within just days. If a wound is not progressing following regular treatment, a more aggressive approach to biofilm removal may be required, with specialist referral as appropriate^[39].

CONCLUSION

Appropriate management of biofilm is arguably a complex task, with various solutions, gels and dressings for its management supported by the literature and clinical experience. The basic steps of initial prevention (with anti-biofilm agents), removal (clean, deslough, debride) and prevention of reformation (use of an antimicrobial agent) provide a framework for the treatment of biofilm; beyond this, myriad patient, environment and clinical parameters must be considered to reach a tailored solution for each patient^[40].

The combination of anti-biofilm agents and antimicrobial agents for biofilm management may occur within the same dressing or their actions may be synergised at dressing change (e.g. using Prontosan solution/gel and Calgitrol Ag). Understanding and keeping up to date with evidence may be challenging, but is a crucial part of any clinician's role if he is to deliver optimal wound care, while being mindful of biofilm management. Caring for the patient holistically and addressing any underlying systemic, psychological or psychosocial issues is also important in underpinning a 'gold standard' care.

REFERENCES

1. James GA, Swogger E, Wolcott R et al. Biofilms in chronic wounds. *Wound Repair Regen* 2008; 16(1): 37-44.
2. Percival S, McCarty S and Lipsky B. Biofilms and wounds: *An overview of the evidence Advances in Wound Care* 2015; 4(7): 373-381.
3. Cooper R, Bjarnsholt T and Alhede M. Biofilms in wounds: A review of present knowledge. *Journal of Wound Care* 2014 23(11): 570-582.
4. Thomson CH. Biofilms: do they affect wound healing? *Int W J* 2011; Feb 8(1):63-7. doi: 10.1111/j.1742-481X.2010.00749.x. Epub 2010 Dec.
5. Keast D, Swanson T, Carville K, Fletcher J, Schultz G and Black J. Top Ten Tips: Understanding and managing wound biofilm. *Wound International* 2014; 5(20): 1-4.
6. Swanson T, Grothier L, Schultz G. *Wound Infection Made Easy*. Wounds International 2014. Available from: www.woundsinternational.com.
7. Kim M, Ashida H, Ogawa M, Yoshikawa Y, Mimuro H, Sasakawa C. Bacterial interactions with the host epithelium. *Cell Host Microbe* 2010; 8(1):20-35.
8. Zhao GE, Usui ML, Lippmann SI, et al. Biofilms and Inflammation in Chronic Wounds. *Adv Wound Care (New Rochelle)* 2013; Sep 2(7): 389-399.
9. Wolcott. The role of Biofilm: Are we hitting the Right target? *Plast Reconstr Surg* 2011; January Suppl 127: 28S-35S.
10. Leaper D. Practice development - Innovations. Expert commentary. *Wounds International* 2010; 3(1): 19

11. Leaper DJ, Schultz G, Carville K, Fletcher J, Swanson T and Drake R. Extending the TIME concept: what have we learned in the past 10 years? *Int W J* 2010; 9(Suppl 2): 1-19.
12. Metcalf D, Bowler P, Hurlow J. *Development of an algorithm for wound biofilm identification*. Poster presented at EWMA 2013. Available at: http://old.ewma.org/fileadmin/user_upload/EWMA/P314.pdf
13. Percival SL, Vuotto C, Donelli G, Lipsky BA. Biofilms and Wounds: An identification algorithm and potential treatment options. *Advances in Wound Care* 2015; 4(7): 389-397.
14. Phillips PL, Wolcott RD, Fletcher J, et al. *Biofilms Made Easy*. Wounds International 2010; 1(3): S1-S6.
15. Wolcott R. Economic aspects of biofilm based wound care in diabetic foot ulcers. *Journal of Wound Care* 2015; 24(5): 189-194.
16. Hurlow J, Couch K, Laforet K, Bolton L, Metcalf D and Bowler P. Clinical Biofilms: A Challenging Frontier in Wound Care. *Advances in Wound Care* 2015; 4(5): 295-301.
17. Cooper R, Jenkins L and Hooper S. Inhibition of biofilms of *Pseudomonas aeruginosa* by medihoney in vitro. *J Wound Care* 2014; 23(3): 93-104.
18. Finnegan S and Percival SL. EDTA: An antimicrobial and antibiofilm agent for use in wound care. *Advances in Wound Care* 2015; 4(7): 415-421.
19. Wolcott R. Disrupting the biofilm matrix improves wound outcomes. *J Wound Care* 2015; 24(8): 366-371.
20. Rhoads DD, Wolcott RD, Percival SL. Biofilms in wounds: management strategies. *J Wound Care* 2008; Nov 17(11):50-8.
21. Bradbury S and Fletcher J. *Prontosan Made Easy*. Wounds International 2011; 2(2).
22. *JWC Wound Care Handbook 2016-2017*. London 2016. MA Healthcare Limited.
23. Bellingeri A et al. Effect of a wound cleansing solution on wound bedpreparation and inflammation in chronic Wounds: a single-blind RCT. *J Wound Care* 2016; 25: 3, 160-168.
24. Percival and Suliman. Slough and biofilm: removal of barriers to wound healing by desloughing. *Journal of Wound Care* 2015; 24(11): 498-510.
25. Vowden K and Vowden P. *Debridement Made Easy*. Wounds UK 2011; 7(4).
26. *Debrisoft: Making the case*. Wounds UK 2015. London.
27. Downe A. How wound cleansing and debriding aids management and healing. *Journal of Community Nursing* 2014; 28(4): 33-37.
28. Rycerz A, Vowden K, Warner V, Jørgensen BF. *VAC Ultra NPWT System Made Easy*. Wounds International 2012; 3(3).
29. Metcalf DG, Parsons D, Bowler PG. Clinical safety and effectiveness evaluation of a new antimicrobial wound dressing designed to manage exudate, infection and biofilm. *IWJ* 2016; Mar 1.
30. Bjarnsholt T, Alhede M, Østrup Jensen P, Nielsen AK, Krogh Johansen H, Homøe P, Høiby N, Givskov M and Kirketerp-Møller K. Antibiofilm properties of acetic acid. *Advances in Wound Care* 2015; 4(7): 363-372.
31. Halstead FD, Webber MA, Rauf M, Burt R, Dryden M, and Oppenheim BA. In vitro activity of an engineered honey, medical grade honeys and antimicrobial wound dressings against biofilm producing clinical bacterial isolates. *Journal of Wound Care* 2016; 25(2): 93-102.
32. Hoekstra MJ, Westgate SJ, Mueller S. Povidone-iodine ointment demonstrates in vitro efficacy against biofilm formation. *International Wound Journal* 2016; doi: 10.1111/iwj.12578. [Epub ahead of print]
33. Percival SL, Finnegan S, Donelli G, Vuotto C, Rimmer S, Lipsky BA (2016) Antiseptics for treating infected wounds: Efficacy on biofilms and effect of pH. *Crit Rev Microbiol* 2016; 42(2): 293-309.
34. Thorn RM, Austin AJ, Greenman J, Wilkins JP, Davis PJ (2009). In vitro comparison of antimicrobial activity of iodine and silver dressings against biofilms. *Journal of Wound Care* 2009; 18(8): 343-6.
35. Lenselink E, Andriessen A. A cohort study on the efficacy of a polyhexanide-containing biocellulose dressing in the treatment of biofilms in wounds. *Journal of Wound Care* 2011; 20(11): 534-539.
36. Percival S and McCarty S. Silver and alginates: Role in wound healing and biofilm control. *Advances in Wound Care* 2015; 4(7): 407-414.
37. Cooper R and Jenkins L. Binding of two bacterial biofilms to dialkyl carbamoyl chloride (DACC) - coated dressings in vitro. *Journal of Wound Care* 2016; 25(2): 6-82.
38. Butcher M. Catch or kill. How DACC technology redefines antimicrobial management. *Br J Comm Nurs* 2011 (Suppl).
39. Wolcott RD, Rhoads DD. A study of biofilm based wound management in subjects with critical limb ischaemia. *J Wound Care* 2008; 17(4): 145-55.
40. *International consensus*. Appropriate use of silver dressings in wounds. An expert working group consensus. London: Wounds International, 2012. Available to download from: www.woundsinternational.com.

Biofilm research: filling in the gaps in knowledge in chronic wounds

The initial hypothesis that bacteria in biofilm structures was an important factor that contributed to chronic refractory infections originated from studies in the early 1980s of diseases including endocarditis, osteomyelitis, periodontitis and cystic fibrosis^[1]. Following these initial studies, extensive laboratory and clinical research publications have confirmed that bacterial biofilms are a critical factor in multiple diseases that are characterised by persistent bacterial infections that are tolerant to a patient's own immune system (antibodies and phagocytic inflammatory cells) and to standard duration regimens of oral (or topical, IV) antibiotics^[2-4].

This important concept was expanded in a landmark paper published in *Science*^[5] in 1999. The paper integrated the concept of biofilm-stimulated chronic inflammation leading to elevated proteases and Reactive Oxygen Species (ROS) that damaged surrounding tissue, which could lead to tissue destruction as in periodontal disease or impairment of organ function by scar formation (fibrosis) as in cystic fibrosis. Recognising that chronic skin wounds have many of the same clinical manifestations as most other diseases with chronic inflammation associated with bacterial biofilms, James and colleagues (2008)^[6] published the initial report of biofilm structures in chronic wounds. Using light and scanning electron microscopy to examine specimens from 66 subjects, they found biofilm structures present in a high percentage (~60%) of 50 chronic wound biopsies in contrast to only 1 of 16 (6%) acute wound specimens. This paper helped to draw attention to the possible critical roles that bacterial biofilms could play in development and maintenance of chronic skin wounds.

Greg Schultz,

Institute for Wound Research, Department of Obstetrics & Gynecology, University of Florida,

Thomas Bjarnsholt,

Costerton Biofilm Center, Department of Immunology & Microbiology, Faculty of Health and Medical Sciences, The University of Copenhagen and Department of Clinical Microbiology, Rigshospitalet, Denmark, **Klaus Kirketerp-Møller**, Copenhagen Wound Healing Center, Bispebjerg University Hospital, Copenhagen, Denmark,

Rose Cooper, Cardiff School of Health Sciences, Cardiff Metropolitan University, Cardiff, UK

RELATIONSHIP BETWEEN BIOFILMS AND CHRONIC WOUND PATHOPHYSIOLOGY

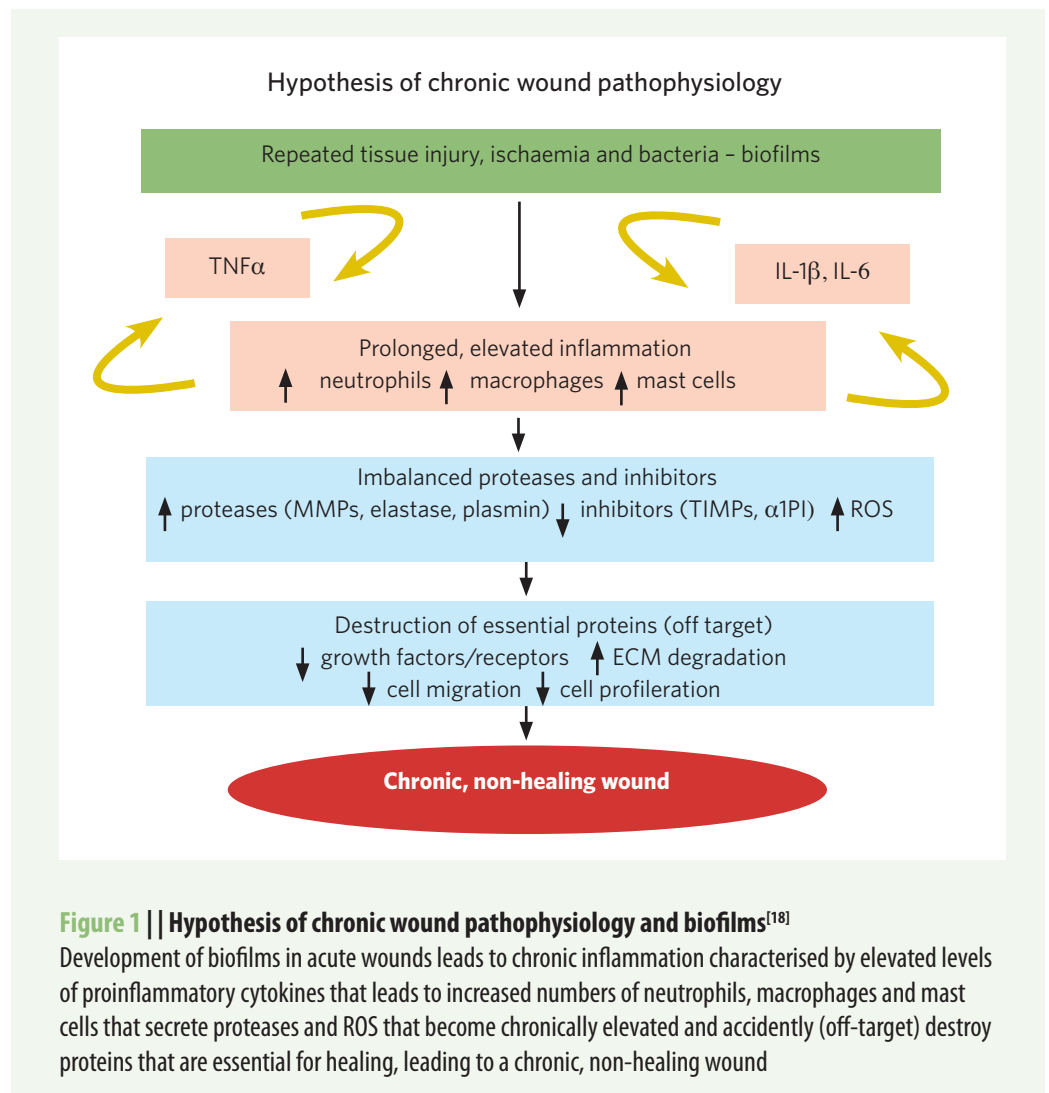
Independent of the research on bacterial biofilms in chronic wounds, multiple laboratories were actively investigating the molecular difference between healing and chronic wounds. Among the first major molecular differences that were identified was the substantial elevation in two major families of proteases in chronic wounds, the matrix metalloproteases (MMPs) and the neutrophil elastase (NE), a member of the serine protease superfamily^[7-13]. Several detrimental effects on healing were attributed to the elevated protease activities in chronic wounds. These included:

- Destruction of important extracellular matrix (ECM) proteins including the multi-domain adhesion protein, fibronectin^[7,14], that is important in epithelial cell migration
- Destruction of important growth factors including platelet derived growth factor (PDGF)^[15]
- Degradation of key membrane receptor proteins for growth factors^[16].

Similarly, elevations in proinflammatory cytokines, including tumor necrosis factor alpha (TNF α) and interleukin-1 alpha (IL1 α), were also reported in chronic wound fluid samples or biopsies compared to healing wounds.⁽¹⁷⁾ All these data pointed to a common pathological pathway in which the development of bacterial biofilms in acute wounds stimulates chronic inflammation, indicated by persistently elevated levels of proinflammatory cytokines (TNF α and IL1 α). These proinflammatory cytokines

chemotactically draw inflammatory cells (neutrophils, macrophages and mast cells) into the wound bed where they secrete proteases (MMPs and NE) and release ROS. The chronically elevated levels of proteases and ROS eventually have ‘off target’ effects that damage or degrade proteins that are essential for healing, converting a healing wound into a stalled, chronic wound (Figure 1)^[18].

In addition, the presence of *Pseudomonas aeruginosa* in biofilms have been hypothesised by Bjarnsholt and colleagues^[19] to produce a ‘shielding’ mechanism that offers protection from the phagocytic activity of PMNs by synthesising and secreting virulence factors, including a rhamnolipid that efficiently eliminates PMNs (by lysis) and the enzyme catalase that degrades hydrogen peroxide, a major ROS produced by PMNs, to non-toxic products oxygen and water.



A GAP IN THE KNOWLEDGE BASE

Detection and measurement of biofilm bacteria in wounds

Based on apparent correlation between chronic wound pathophysiology and the presence of biofilms in a high percentage of chronic wounds, the detection and localisation of biofilms in chronic wound beds provides useful clinical information, especially for assessing and directing the effectiveness of debridement. In addition, assessing the biofilm status of a chronic wound could potentially indicate when a chronic wound bed

is adequately prepared to be able to respond to advanced therapies such as growth factors, advanced matrix dressings, cell-based therapies or skin grafts^[20,21]. However, most clinical microbiology and pathology laboratories use conventional techniques (scanning, sequencing and sampling) that are not able to distinguish between bacteria that were existing either planktonically or within a biofilm^[22]. Thus, clinicians should assume that the reported bacteria are biofilms and should treat them accordingly.

Furthermore, multiple studies have reported that conventional culture methods used by clinical microbiology laboratories to assess the bioburden in wound samples are biased to detecting easily cultured planktonic organisms and fail to detect many bacterial species, especially anaerobic bacteria, as well as fungal and yeast species^[23-26]. For example, Dowd and colleagues (2008)^[23] reported that standard culturing techniques identified only 1% of all microorganisms present in samples of 30 chronic wounds, especially strict anaerobes.

Thomsen and colleagues (2010)^[26] reported similar results when using DNA-based identification techniques and fluorescence *in situ* hybridisation to identify bacterial species in 14 ulcers undergoing skin graft operations. They found substantial differences between results obtained by standard culture-based methods and molecular-biology-based methods.

Expanding their initial study, Wolcott and colleagues (2016)^[27] used 16S rDNA pyrosequencing to analyse the microbiota of 2,963 samples from chronic venous leg ulcers (n=916), diabetic foot ulcers (910), decubitus ulcers (767) and non-healing surgical wounds (370). They found similar profiles for the 20 bacterial species most frequently identified in each of the four types of chronic wounds, with *Staphylococcus* and *Pseudomonas* species comprising the most prevalent genera. In addition, strict anaerobes comprised 4 of the top 10 genera detected in the chronic wound samples. Commensal microorganisms, including coagulase-negative *Staphylococcus*, *Corynebacterium* and *Propionibacterium*, were present in nearly half of the chronic wound samples tested, but further research is needed to assess whether the presence of these organisms affect the healing of chronic wounds.

It is important to understand that using both culture and DNA-based methods to detect bacterial species present in wound samples does not differentiate between bacteria growing planktonically or growing in biofilm communities. This can only be accomplished by microscopy or by selective culturing for biofilms as described below.

Does biofilm-based wound care improve healing of chronic wounds?

An important question to ask is: 'Does more accurately knowing the actual bacterial, fungal and yeast species present in chronic wounds, including bacteria in biofilms, actually provide important information that a clinician can use to improve healing outcomes?' In a large, level A, retrospective cohort study, implementation of personalised topical therapeutics guided by molecular diagnosis of bacterial species resulted in statistically and clinically significant improvements in healing^[28].

In the standard of care (SOC) group, 48.5% of patients (244/503) healed completely during the 7-month study period; this increased to 62.4% (298/479) in the treatment group that received SOC plus systemic antibiotics based on the results of molecular identification of wound bacteria. Completed healing further increased to 90.4% (358/396) in the treatment group that received SOC plus topical therapeutics (including antibiotics) based on the results of molecular diagnostics ($p < 0.001$ compared to SOC or SOC + systemic antibiotics, Cox proportional hazards analysis). More recently, Wolcott (2015)^[29] reported significantly increased healing of wounds treated with SOC combined with a hydrogel that contained topical antibiotics and agents that disrupted biofilms.

How and where to sample a chronic wound bed for biofilm

Currently, detecting and localising biofilms in chronic skin wound beds is one of the most important 'gaps in the knowledge base' for biofilm-based wound care, especially since mature, tolerant biofilms can reform within three days following effective debridement of chronic skin wounds^[30,31].

In May 2015, the European Society for Clinical Microbiology and Infectious Diseases (ESCMID) published guidance for diagnosis and treatment of biofilm infections^[32]. It includes information and guidelines on detecting and treating biofilm infections in multiple conditions. These included tissues/mucus infections, such as in patients with chronic lung infections (cystic fibrosis), and in chronic infections where biofilms form on devices inside the body (orthopaedic implants, breast implants) or on devices that connect between the inner (sterile) and outer surface of the body such as intravenous catheters, indwelling urinary catheters or endotracheal tubes. The target readers for this guideline are clinical microbiologists and infectious disease specialists involved in diagnosis and management of biofilm infections.

The ESCMID guideline states: '*Biopsy tissues are considered the most reliable samples to reveal biofilm in wounds. The use of swabs to collect biofilm samples from the wound surface is considered an inadequate method, due to contamination from the skin flora, the strong adherence of biofilm to the host epithelium and the growth of anaerobes in the deep tissues. If a moderate to severe soft tissue infection is suspected and a wound is present, a soft tissue sample from the base of the debrided wound should be examined. If this cannot be obtained, a superficial swab may provide useful information on the choice of antibiotic therapy*'^[33,34].

However, assuming a biopsy or curettage wound sample can be obtained from the chronic skin wound, this guideline leaves several important questions unanswered, including:

- Where in the wound bed should a single sample be taken?
- Is one biopsy sufficient to confidently assess if a chronic wound has (or does not have) a mature biofilm? It is highly unlikely that biofilms are uniformly present over the entire wound bed and edge of the wound, so what should guide the clinician?
- Are there any visual signs that might be useful in deciding where to take the single biopsy?

Several papers have reported that the distribution of biofilm aggregates throughout chronic wound beds is not uniform^[35,36]. For example, as shown in Figure 2, aggregates of *P. aeruginosa* biofilms are not homogeneously distributed on the chronic wound bed^[36].




Figure 2 | Biofilms of *P. aeruginosa* in a chronic wound visualised using a specific peptide nucleic acid-fluorescence *in situ* hybridisation probe (red) with confocal laser scanning microscopy. The right image shows an enlargement of the middle image. The distribution of biofilm colonies on the wound bed surface is not uniform^[36]

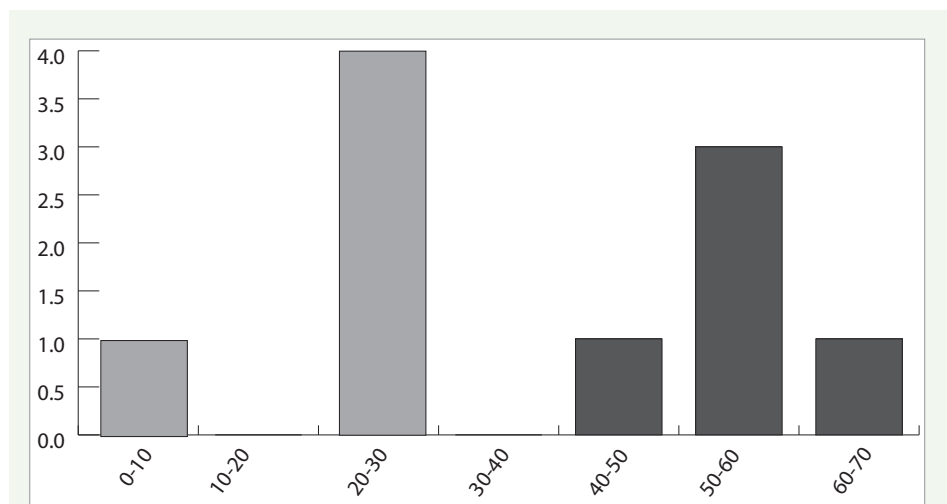


Figure 3 | Distribution of the distances from the wound surface to the centre of mass of *S. aureus* aggregates (light grey shading) or *P. aeruginosa* aggregates (dark grey shading). The distances are average values obtained from the analysis of 15 images for each of 9 chronic wound samples.

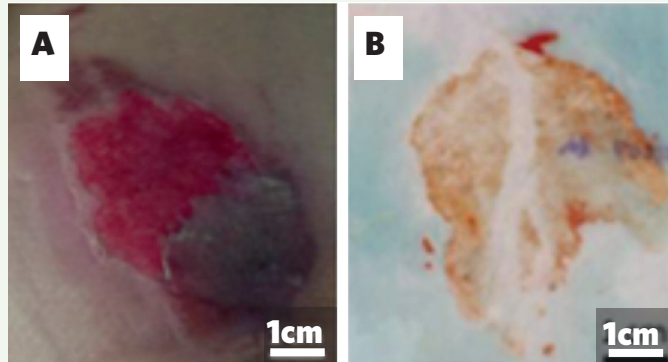
In addition, aggregates of biofilms are not necessarily present only on the surface of wound beds^[35]. As shown in Figure 3, biofilm structures were identified beneath the surface of 9 chronic wound beds, with *S. aureus* aggregates nearer the surface of the wound bed (~20-30 micron depth) compared to *P. aeruginosa* aggregates (50-60 micron depth). It is most likely that different species or phenotypes of bacteria prefer environmental niches. Also, distribution of bacteria and biofilms could also be dependent on competition or collaboration with other microorganisms^[26,36].

As explained in the accompanying article by Bjarnsholt et al (pages 4-8)^[37], there has been considerable debate over whether biofilms in chronic wound beds can be visually observed by clinicians. While large formations of biofilms on the enamel surface of teeth can be visualised by 'disclosing dyes', it is less clear if all biofilm formations can be visualised in chronic wounds. Some clinicians have proposed that 'clinical signs' such as a shiny, translucent, slimy layer on non-healing wound beds that quickly reform when debrided, may be easier to remove by fabric pads, and may be less responsive to enzymatic or autolytic debridement are likely to be biofilms^[38,39]. However, these observations need to be supported by rigorous analysis of these types of materials on wound beds for biofilms.

A new 'biofilm wound map' technique described by Nakagami and colleagues^[40] may provide useful information on localising biofilms in the surface of a wound bed. A clinician presses a highly positively charged nylon membrane onto the wound bed for a few minutes, which produces a 'molecular imprint' of the molecules on the wound bed surface that are very tightly bound to the membrane. The 'blot' is then submerged for a few seconds in a solution containing a positively charged dye molecule (such as ruthenium red) that ionically binds to highly negatively charged molecules bound on the membrane, and then briefly rinsed. Most bacterial biofilms contain substantial amounts (~20%) of free bacterial DNA, which is highly negatively charged^[41].

Laboratory experiments demonstrated that areas of the membrane that retain the dye correspond to areas on a wound bed surface that have an exopolymeric matrix of biofilm communities. Furthermore, the amount of surface area of a wound bed that generated

Figure 4 | Biofilm Wound Map. Orange-red staining present on the membrane (panel B) suggests the presence of biofilm exopolymeric matrix of chronic wound (panel A) blotted onto a positively charged membrane



staining on the membrane predicted the extent of slough that developed on the chronic wound bed during the following week. A weakness of this technique is that would preferentially detect biofilm exopolymeric matrix located on the surface of the wound bed, and not detect biofilm exopolymeric matrix buried deep in the wound bed matrix. Clearly, there is a need to develop a rapid, inexpensive, and easy-to-use biofilm detector that can be used at the point-of-care in a few minutes.

WHAT IS THE OPTIMAL BIOFILM ASSAY(S) FOR CHRONIC WOUNDS?

Several different assays are used to determine if a wound sample contains a mature tolerant biofilm. The most common approach is to visualise biofilm-like structures using either light microscopy, often with antibodies that detect a unique component of the exopolymeric matrix of some biofilms such as alginate synthesised by *P. aeruginosa*, or fluorescence in situ hybridisation (FISH). However, it can take several days to process tissue samples through paraffin embedding. Cryosectioning may offer faster processing and evaluation. Both techniques require expensive microscopes and trained technicians, and cannot be done during a clinic visit.

Most standard clinical microbiology laboratories can adopt a relatively simple and standard approach to measuring bacteria in protective biofilms^[42]. Briefly, wound samples are placed in phosphate buffered saline (PBS) containing 5 ppm Tween 20 (5 ml/ml). They are vortexed to suspend tissue after which dilute bleach to a final concentration of 0.03% is added.

The samples are then incubated for 10 minutes to kill all planktonic bacteria and the bleach is neutralised with sodium metabisulfite (0.3% final concentration). The biofilm aggregate is then dispersed in to single bacteria by five, 1.5-minute cycles of sonication with a 1 minute cooling pause between sonication cycles. Samples are plated by 10-fold dilutions onto selective growth agar plates and colonies counted after 24 hours and 48 hours of incubation at 37°C.

Alternatively, wound samples can be placed into solutions containing antibiotics (gentamicin, moxifloxacin, penicillin) for 24 hours at 37°C to kill susceptible planktonic bacteria then washed twice in Dey-Engley neutralising broth, vortexed (30 seconds), sonicated (two minutes), and vortexed (30 seconds) three times, to disperse biofilms into single cell suspensions that are then serially diluted with PBS, plated on TSB and the plates were incubated at 37°C for 24–48 hours^[43].

CAN WOUNDS HEAL WITH A SMALL AMOUNT OF BIOFILM?

Many acute wounds can heal despite bacterial colonisation. This is a paradox that may be explained by hypothesising that the immune system of most patients (sometimes supplemented by systemic antibiotics or topical antiseptic dressings) can kill planktonic bacteria before they develop into biofilms that are very difficult to kill. Most chronic wounds have become chronic due to maltreatment, and they undoubtedly have substantial amounts of bacterial biofilm, but when many chronic wounds receive correct treatment such as compression and/or off-loading, they start to heal, even without adding antibiotics or antiseptics. It is possible that this may be explained by the fact that some bacteria are more virulent like *Pseudomonas* and some *Staphylococcus* strains^[19], but many of the bacteria in the wounds are opportunistic infectious agents. The immune response might create opportunities for less virulent bacteria, fighting for the same space, to influence the bacteria in the biofilm. Clearly, this is an important question that further research needs to address.

CONCLUSION

Bacterial biofilm can play a pivotal role in the development and maintenance of chronic wounds. The detection and localisation of biofilms in chronic wounds provide useful clinical information, in particular in assessing and directing the effectiveness of debridement. However, gaps in the knowledge base remain when it comes to detecting and localising biofilms in chronic wounds. The ESCMID guideline^[32] published in 2015 offers direction on diagnosis and treatment of biofilm infection but leaves some questions unanswered, including whether visual signs might be useful in deciding where to take a biopsy.

The debate surrounding whether or not biofilm can be seen with the naked eye continues. New techniques, such as the 'biofilm wound map' from Nagakami and colleagues^[40] may provide useful information on localising biofilms in the surface of the wound bed. However, as with other existing techniques, this has its weaknesses and there remains a need to develop a point-of-care biofilm detector that can provide results in a few minutes not a few days. More focused research is needed to accurately and effectively detect and localise biofilms in chronic wounds.

REFERENCES

1. Costerton JW. The etiology and persistence of cryptic bacterial infections: a hypothesis. *Rev Infect Dis* 1984; 6 Suppl 3:S608-S616.
2. Costerton JW, Cheng KJ, Geesey GG, Ladd TI, Nickel JC, Dasgupta M, Marrie TJ. Bacterial biofilms in nature and disease. *Annu Rev Microbiol* 1987v;41:435-64.
3. Costerton JW, Lewandowski Z, Caldwell DE, Korber DR, Lappin-Scott HM. Microbial biofilms. *Annu Rev Microbiol* 1995; 49:711-45.
4. Donlan RM, Costerton JW. Biofilms: survival mechanisms of clinically relevant microorganisms. *Clin Microbiol Rev* 2002; 15(2):167-93.
5. Costerton JW, Stewart PS, Greenberg EP. Bacterial biofilms: a common cause of persistent infections. *Science* 1999; 284(5418):1318-22.
6. James GA, Swogger E, Wolcott R, Pulcini ED, Secor P, Sestrich J, Costerton JW, Stewart PS. Biofilms in chronic wounds. *Wound Repair Regen* 2008; 16(1):37-44.
7. Wysocki AB, Grinnell F. Fibronectin profiles in normal and chronic wound fluid. *Lab Invest* 1990; 63(6):825-31.
8. Ladwig GP, Robson MC, Liu R, Kuhn MA, Muir DF, Schultz GS. Ratios of activated matrix metalloproteinase-9 to tissue inhibitor of matrix metalloproteinase-1 in wound fluids are inversely correlated with healing of pressure ulcers. *Wound Repair Regen* 2002; 10(1):26-37.
9. Trengove NJ, Stacey MC, Macauley S, Bennett N, Gibson J, Burslem F, Murphy G, Schultz G. Analysis of the acute and chronic wound environments: the role of proteases and their inhibitors. *Wound Repair Regen* 1999; 7(6):442-52.
10. Beidler SK, Douillet CD, Berndt DF, Keagy BA, Rich PB, Marston WA. Multiplexed analysis of matrix metalloproteinases in leg ulcer tissue of patients with chronic venous insufficiency before and after compression therapy. *Wound Repair Regen* 2008; 16(5):642-8.
11. Liu Y, Min D, Bolton T, Nube V, Twigg SM, Yue DK, McLennan SV. Increased matrix metalloproteinase-9 predicts poor wound healing in diabetic foot ulcers. *Diabetes Care* 2009; 32(1):117-9.
12. Rayment EA, Upton Z, Shooter GK. Increased matrix metalloproteinase-9 (MMP-9) activity observed in chronic wound fluid is related to the clinical severity of the ulcer. *Br J Dermatol* 2008; 158(5):951-61.
13. Lobmann R, Ambrosch A, Schultz G, Waldmann K, Schiweck S, Lehnert H. Expression of matrix-metalloproteinases and their inhibitors in the wounds of diabetic and non-diabetic patients. *Diabetologia* 2002; 45(7):1011-6.
14. Herrick SE, Sloan P, McGurk M, Freak L, McCollum CN, Ferguson MW. Sequential changes in histologic pattern and extracellular matrix deposition during the healing of chronic venous ulcers. *Am J Pathol* 1992; 141(5):1085-95.
15. Pierce GF, Tarpley JE, Tseng J, Bready J, Chang D, Kenney WC, Rudolph R, Robson MC, Vande Berg J, Reid P, . Detection of platelet-derived growth factor (PDGF)-AA in actively healing human wounds treated with recombinant PDGF-BB and absence of PDGF in chronic nonhealing wounds. *J Clin Invest* 1995; 96(3):1336-50.
16. Cowin AJ, Hatzirodos N, Holding CA, Dunaiski V, Harries RH, Rayner TE, Fitridge R, Cooter RD, Schultz GS, Belford DA. Effect of healing on the expression of transforming growth factor beta(s) and their receptors in chronic venous leg ulcers. *J Invest Dermatol* 2001; 117(5):1282-9.
17. Trengove NJ, Bielefeldt-Ohmann H, Stacey MC. Mitogenic activity and cytokine levels in non-healing and healing chronic leg ulcers. *Wound Repair Regen* 2000; 8(1):13-25.
18. Mast BA, Schultz GS. Interactions of cytokines, growth factors, and proteases in acute and chronic wounds. *Wound Repair Regen* 1996; 4(4):411-20.
19. Bjarnsholt T, Kirketerp-Møller K, Jensen PO, Madsen KG, Phipps R, Krogfelt K, Hoiby N, Givskov M. Why chronic wounds will not heal: a novel hypothesis. *Wound Repair Regen* 2008; 16(1):2-10.
20. Wolcott RD, Kennedy JP, Dowd SE. Regular debridement is the main tool for maintaining a healthy wound bed in most chronic wounds. *J Wound Care* 2009; 18(2):54-6.
21. Wolcott RD, Cox S. More effective cell-based therapy through biofilm suppression. *J Wound Care* 2013;22(1):26-31.
22. Costerton JW, Post JC, Ehrlich GD, Hu FZ, Kreft R, Nistico L, Kathju S, Stoodley P, Hall-Stoodley L, Maale G, James G, Sotereanos N, DeMeo P. New methods for the detection of orthopedic and other biofilm infections. *FEMS Immunol Med Microbiol* 2011; 61(2):133-40.
23. Dowd SE, Sun Y, Secor PR, Rhoads DD, Wolcott BM, James GA, Wolcott RD. Survey of bacterial diversity in chronic wounds using Pyrosequencing, DGGE, and full ribosome shotgun sequencing. *BMC Microbiol* 2008; 8(1):43.
24. Dowd SE, Delton HJ, Rees E, Wolcott RD, Zischau AM, Sun Y, White J, Smith DM, Kennedy J, Jones CE. Survey of fungi and yeast in polymicrobial infections in chronic wounds. *J Wound Care* 2011; 20(1):40-7.

25. Dowd SE, Wolcott RD, Sun Y, McKeehan T, Smith E, Rhoads D. Polymicrobial nature of chronic diabetic foot ulcer biofilm infections determined using bacterial tag encoded FLX amplicon pyrosequencing (bTEFAP). *PLoS ONE* 2008; 3(10):e3326.
26. Thomsen TR, Aasholm MS, Rudkjøbing VB, Saunders AM, Bjarnsholt T, Givskov M, Kirketerp-Møller K, Nielsen PH. The bacteriology of chronic venous leg ulcer examined by culture-independent molecular methods. *Wound Repair Regen* 2010; 18(1):38-49.
27. Wolcott RD, Hanson JD, Rees EJ, Koenig LD, Phillips CD, Wolcott RA, Cox SB, White JS. Analysis of the chronic wound microbiota of 2,963 patients by 16S rDNA pyrosequencing. *Wound Repair Regen* 2016; 24(1):163-74.
28. Dowd SE, Wolcott RD, Kennedy J, Jones C, Cox SB. Molecular diagnostics and personalised medicine in wound care: assessment of outcomes. *J Wound Care* 2011; 20(5):232, 234-2, 239.
29. Wolcott R. Disrupting the biofilm matrix improves wound healing outcomes. *J Wound Care* 2015; 24(8):366-71.
30. Wolcott RD, Rhoads DD. A study of biofilm-based wound management in subjects with critical limb ischaemia. *J Wound Care* 2008; 17(4):145-2, 154.
31. Shin KS, Song HG, Kim H, Yoon S, Hong SB, Koo SH, Kim J, Kim J, Roh KH. Direct detection of methicillin-resistant *Staphylococcus aureus* from blood cultures using an immunochromatographic immunoassay-based MRSA rapid kit for the detection of penicillin-binding protein 2a. *Diagn Microbiol Infect Dis* 2010; 67(3):301-3.
32. Hoiby N, Bjarnsholt T, Moser C, Bassi GL, Coenye T, Donelli G, Hall-Stoodley L, Hola V, Imbert C, Kirketerp-Møller K, Lebeaux D, Oliver A, Ullmann AJ, Williams C. ESCMID guideline for the diagnosis and treatment of biofilm infections 2014. *Clin Microbiol Infect* 2015; 21 Suppl 1:S1-25.
33. Percival SL, Hill KE, Williams DW, Hooper SJ, Thomas DW, Costerton JW. A review of the scientific evidence for biofilms in wounds. *Wound Repair Regen* 2012; 20(5):647-57.
34. Lipsky BA, Berendt AR, Cornia PB, Pile JC, Peters EJ, Armstrong DG, Deery HG, Embil JM, Joseph WS, Karchmer AW, Pinzur MS, Senneville E. Executive summary: 2012 Infectious Diseases Society of America clinical practice guideline for the diagnosis and treatment of diabetic foot infections. *Clin Infect Dis* 2012; 54(12):1679-84.
35. Fazli M, Bjarnsholt T, Kirketerp-Møller K, Jørgensen B, Andersen AS, Kroghfelt KA, Givskov M, Tolker-Nielsen T. Nonrandom distribution of *Pseudomonas aeruginosa* and *Staphylococcus aureus* in chronic wounds. *J Clin Microbiol* 2009; 47(12):4084-9.
36. Bjarnsholt T. The role of bacterial biofilms in chronic infections. *Acta Pathologica Microbiologica et Immunologica Scandinavica* 2013; 121(Suppl 136):S1-S51.
37. Bjarnsholt T, Schultz GS, Kirketerp-Møller K, Fletcher J, Malone M. The role of biofilms in delayed wound healing. *Wounds International* 2016.
38. Metcalf DG, Bowler PG, Hurlow J. A clinical algorithm for wound biofilm identification. *J Wound Care* 2014; 23(3):137-2.
39. Hurlow J, Bowler PG. Potential implications of biofilm in chronic wounds: a case series. *J Wound Care* 2012; 21(3):109-10, 112, 114.
40. Nakagami G, Schultz G, Gibson D, Phillips P, Kitamura A, Minematsu T, Miyagaki T, Hayashi A, Sasaki S, Sugama J, Sanada H. *Biofilm detection by wound blotting can predict slough development in pressure ulcers: a prospective observational study*. Submitted 2016.
41. Spoering AL, Gilmore MS. Quorum sensing and DNA release in bacterial biofilms. *Curr Opin Microbiol* 2006 9(2):133-7.
42. Fennelly KP, Ojano-Dirain C, Yang Q, Liu L, Lu L, Progulske-Fox A, Wang GP, Antonelli P, Schultz G. Biofilm Formation by *Mycobacterium abscessus* in a Lung Cavity. *Am J Respir Crit Care Med* 2016; 193(6):692-3.
43. Wolcott RD, Rumbaugh KP, James G, Schultz G, Phillips P, Yang Q, Watters C, Stewart PS, Dowd SE. Biofilm maturity studies indicate sharp debridement opens a time- dependent therapeutic window. *J Wound Care* 2010; 19(8):320-8.

NOTES



A Wounds International publication
www.woundsinternational.com